

Anterior vaginal prolapse repair: A randomised trial of traditional anterior colporrhaphy and self-tailored mesh repair

B Gupta, MD; N B Vaid, MD; A Suneja, MD; K Guleria, MD; S Jain, MD

University College of Medical Sciences and Guru Tegh Bahadur Hospital, Dilshad Garden, Delhi, India

Corresponding author: B Gupta (dr_bindiya_gupta@yahoo.co.in)

Background. Anterior colporrhaphy has been the traditional standard surgical treatment for anterior vaginal prolapse. However, since it is associated with a 40% recurrence rate, an attempt has been made to resolve the problem of recurrence by means of artificial mesh.

Objective. To compare traditional colporrhaphy with self-tailored mesh in anterior colporrhaphy.

Methods. One hundred and six women were enrolled in a prospective randomised controlled trial and divided into two groups: traditional anterior colporrhaphy ($n=54$) and anterior self-tailored mesh repair ($n=52$). The standard pelvic organ prolapse quantification (POPQ) system was used. Women with symptomatic anterior vaginal prolapse \geq POPQ stage II were included. Those with concomitant stress urinary incontinence, dominant posterior vaginal prolapse, active vaginal infections and suspected malignancy were excluded. Outcomes at the end of the procedure, intraoperative and postoperative complications, and follow-up (4 weeks, 6 months, 1 year) were noted. Patients were assessed for recurrence (\geq POPQ stage II), complications, satisfaction and acceptability.

Results. Postoperative outcome was significantly better than preoperative staging, but no significant difference was seen in the two groups. On follow-up, the primary endpoints (Aa, Ba, tVL) did not differ significantly between the two groups. There were more complications in the mesh group. Satisfaction and acceptability were similar in the two groups.

Conclusion. Although the outcomes in the two groups were similar, duration of surgery and blood loss were significantly greater in the mesh group. The use of mesh in anterior prolapse repair needs to be evaluated further.

S Afr J OG 2014;20(2):47-50. DOI:10.7196/SAJOG.749



Pelvic organ prolapse (POP) is common. Up to 50% of parous women have some degree of genital prolapse, although only 10 - 20% are symptomatic.^[1] The lifetime risk of surgery for prolapse is 11% and almost one-third require reoperation.^[2]

Anterior vaginal prolapse is present in up to 33% of postmenopausal women.^[3] Anterior colporrhaphy has been the standard surgical treatment for anterior vaginal prolapse. However, it is associated with a 40% recurrence rate, and up to 32% even after using concomitant paravaginal repair with anterior colporrhaphy.^[4,5] It can also result in additional vaginal shortening or constriction.

An attempt has been made to resolve the problem of recurrence by means of an artificial mesh. The rationale for graft use can be supported by data on incisional hernia repair.^[6,7] Studies have reported low recurrence rates with mesh as compared with traditional colporrhaphy (6.7% v. 38.5%).^[8] Type I, macroporous, polypropylene soft mesh is the ideal choice.^[9] There are different techniques of mesh insertion using either a self-designed mesh or commercially available standard kits for mesh repair.^[8-12] Although sufficient studies of the techniques for mesh placement in anterior colporrhaphy are available, definite recommendations are lacking.

Mesh-related complications include infection, sinus tract formation, erosion, bleeding and discharge, pain and dyspareunia.^[9] The lack of comparative data and the anticipated high incidence of graft-related complications have led to a debate among surgeons regarding the appropriateness of graft use. Regulatory bodies such as the US Food and Drug Administration (FDA) have revised and updated the guidelines of mesh use.^[13]

The aim of the study was to compare the mesh with traditional anterior colporrhaphy in terms of efficacy, complications, satisfaction and acceptability.

Methods

Patients were randomised into two groups: traditional anterior colporrhaphy (group A) and mesh repair of anterior vaginal prolapse (group B). Randomisation was performed using a computer-generated random number table. The number of patients was calculated by power analysis. Type 1 error was assumed to be 5% and power as 80%, with the anticipated recurrence with the traditional method taken as 25% and that with mesh repair 4%. The total number of patients required was therefore calculated to be 106, taking into account patients who would be lost to follow-up.

Patients with symptomatic anterior vaginal prolapse to the hymen or beyond were included in the trial. The exclusion criteria included concomitant stress urinary incontinence, dominant symptomatic posterior vaginal prolapse, active vaginal infections and presence of any gynaecological malignancy. The study was approved by the institutional ethical committee.

The study protocol was explained to patients and informed consent was obtained from all. A detailed urogynaecological and medical history was taken from all patients including data on bowel, urinary and coital symptoms. All patients underwent a comprehensive physical and urogenital examination in the supine position, with and without straining. The prolapse was graded using the standard pelvic organ prolapse quantification (POPQ) system.^[14] Points Aa, Ba and tVL were noted in all patients in preoperative assessment.

Acriflavine-glycerine packing was used if required for 1 week prior to surgery. All patients received preoperative intravenous antibiotics (1 g cefotaxime, 500 mg metronidazole). Additional procedures, including vaginal hysterectomy, McCall's culdoplasty, sacrospinous colpopexy and sacrospinous cervicopexy, were carried out wherever appropriate. Regional anaesthesia was used for the procedure.

In group A, traditional anterior colporrhaphy was performed. A sagittal anterior vaginal wall incision was made extending from the urethrovaginal junction to the vaginal apex. The mucosa was separated from the underlying fibromuscular layer and dissected up to the lateral sulcus. Midline plication of the fibromuscular layer was done with buttressing 2-0 absorbable vicryl suture. The vaginal wall was closed with interrupted 2-0 vicryl mattress sutures.

In group B, anterior colporrhaphy was done using a tailored non-absorbable, low-weight, monofilament, macroporous, vicryl-polypropylene mesh (VYPRO mesh, Johnson & Johnson Inc.) (Fig. 1). Four arms were made from a 6 × 11 cm mesh patch. The anterior border of the mesh was slightly curved to avoid covering the urethrovaginal junction. After separating the fibromuscular layer from the mucosa of the anterior vaginal wall, four tunnels were made by sharp and blunt dissection so that the arms of the mesh could be fixed in place. The anterior tunnels were made along the inside of the inferior rami of the pubic bone, dissecting the fibromuscular layer towards the obturator foramina but not reaching through the obturator membrane. The posterior tunnels were made by dissecting the fibromuscular layer towards the ischial spine. Site-specific repair was done using interrupted 2-0 vicryl sutures. The central area of the mesh was fashioned according to the size of the cystocele. The tailored mesh was placed over partly repaired bladder fascia,



Fig. 1. Self-tailored mesh, with a centre and four arms.

and the arms placed in the tunnels created anteriorly and posteriorly. Mesh was attached to the underlying bladder fascia with interrupted 2-0 vicryl sutures. The vagina was closed as for group A.

All patients received intravenous antibiotics for 48 hours postoperatively (1 g cefotaxime, 500 mg metronidazole). The vaginal pack was removed after 24 hours and the catheter after 24 - 72 hours. All patients were discharged within 72 hours.

Objective measurements were used to rate the efficacy of the procedure. Cure was defined as optimal (when both points Aa and Ba were at stage 0 (-3 cm)) or satisfactory (when both points Aa and Ba were at stage I (-2 cm) and improved from preoperative staging). Outcome was unsatisfactory (failure) when either point Aa or Ba was at stage II or worse (-1 cm or lower) or unchanged or worse than preoperative staging. Intraoperative and postoperative complications were noted in the two groups.

The patients were followed up at 4 weeks, 6 months and 1 year. The primary endpoint was recurrence of anterior wall vaginal prolapse reaching stage II POPQ or more. Secondary endpoints noted were complications including bleeding, discharge, mesh erosion, infection, sinus

formation, etc. Improvement in urinary and bowel symptoms was analysed. Patient satisfaction with and acceptance of the procedure were also assessed by means of a previously validated local questionnaire.

The data were analysed using SPSS version 16.0 (SPSS, USA). Univariate analysis was conducted with Fisher's exact test for categorical variables and the Mann Whitney U-test for continuous variables. The Wilcoxon signed-rank test was used to compare the POPQ measurements before and after the procedure. A *p*-value of <0.05 was considered statistically significant.

Results

One hundred and six women were enrolled and followed up in the study between May 2009 and May 2012; 54 were in group A (traditional anterior colporrhaphy) and 52 in group B (repair with mesh) (Fig. 2). The baseline characteristics were comparable in the two groups (Table 1).

In group A, 52 (96%), 44 (81%) and 41 (76%) patients out of 54 came for follow-up at 4 weeks, 6 months and 1 year, respectively. One patient had vault prolapse at 3 months and was excluded while the rest were lost to follow-up. In group B, 51 (98%), 48 (92%) and 44 (84%) patients out of 52 were followed up at 4 weeks, 6 months

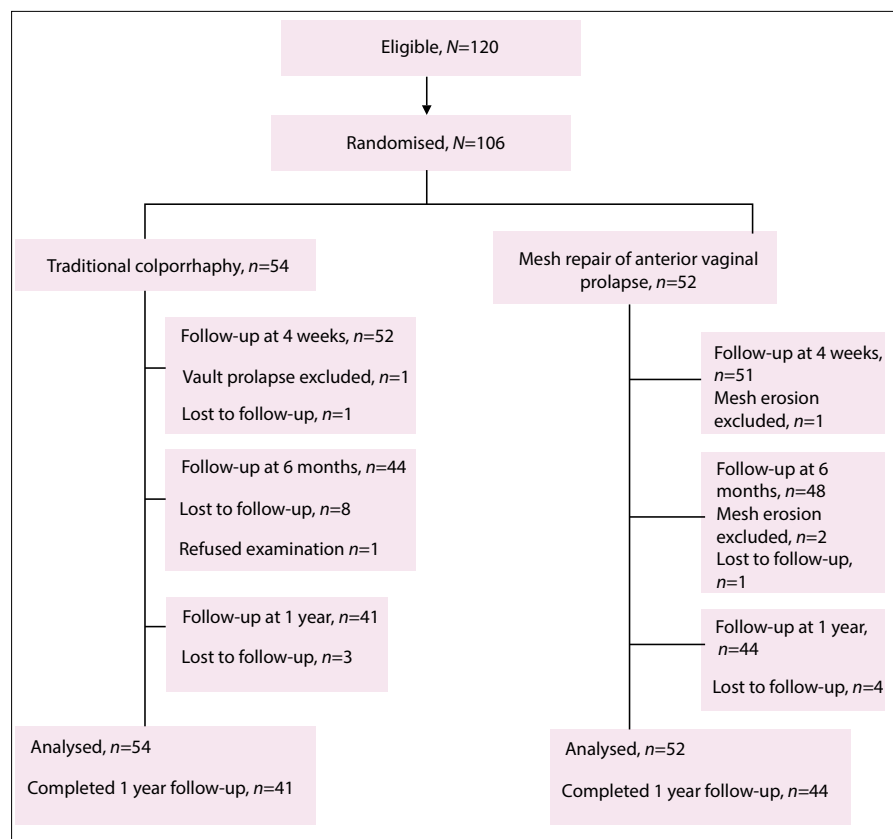


Fig. 2. Flow diagram, including total sample size, randomisation, follow-up and analysis.

Table 1. Baseline characteristics

	Group A (N=54)	Group B (N=52)
Age (years), mean (SD)	51.5 (12)	49.6 (10)
Parity, median (range)	4 (2 - 6)	4 (2 - 7)
Previous LSCS, <i>n</i>	1	0
Postmenopausal, <i>n</i> (%)	40 (74.1)	36 (69.2)
Duration of prolapse (years), median (range)	4 (3 - 7)	4 (2 - 7)
Medical high risk, <i>n</i> (%)		
Hypertension	10 (18.5)	14 (26.9)
Diabetes mellitus	1 (1.9)	-
Prior hysterectomy, <i>n</i> (%)	1 (1.9)	1 (1.9)
Preoperative measurements and staging, median		
Aa (cm)	+3	+3
Ba (cm)	+4	+5
tVL (cm)	+8	+7
POPQ stage	IIIb	IIIb
Haemoglobin (g/dl), mean (SD)	9.6 (1.4)	9.8 (1.1)
Concomitant vaginal hysterectomy, <i>n</i> (%)	53 (98.1)	50 (96.2)
Sacrospinous fixation, <i>n</i> (%)	1 (1.9)	1 (1.9)
Sacrohysteropexy, <i>n</i> (%)	-	1 (1.9)

SD = standard deviation; LSCS = lower-segment caesarean section; POPQ = pelvic organ prolapse quantification.

Table 2. Follow-up in the two groups

	4 weeks		6 months		1 year	
	Group A	Group B	Group A	Group B	Group A	Group B
Measurements (cm), median						
Aa	-3	-3	-3	-3	-3	-2
Ba	-2	-2	-1	-2	-2	-2
tVL	-7	-8	-7	-7	-5	-7
<i>p</i> -value	0.26		0.224		0.34	

and 1 year, respectively. Four patients had mesh erosion and were excluded from assessment of success of the repair.

In the traditional colporrhaphy arm, the outcome was optimal in 55% and satisfactory in 45%; in group B, outcome was optimal in 65% and satisfactory in 35%. There was no significant difference in the outcomes between the two groups ($p=0.4$). There was no procedure failure in both the groups (excluding the vault prolapse). The mean (standard deviation (SD)) duration of surgery was significantly greater in the mesh group, 0.8 (0.27) hours v. 0.4 (0.1) hours ($p=0.02$). Mean (SD) blood loss was 398 (129) ml in the mesh group, which was significantly more than that in group A, 188 (97) ml ($p=0.015$). In group A, blood transfusion was given to 12 patients, 4

had postoperative fever and 1 patient had urinary tract infection. In the mesh group, blood transfusion was given to 19 patients, 2 had an anterior wall haematoma and 1 had overflow incontinence. One patient with vaginal haematoma had mesh erosion through the vaginal wall after 3 weeks and was excluded.

The follow-up of patients in both groups is shown in Table 2. Follow-up was limited to telephonic interview in some cases and accompanied by formal examination in others. The primary outcomes in the two groups at various intervals were not significantly different. In group A, 15 patients complained of vaginal discharge and 2 (3.7 %) had a recurrent cystocele (stage II POPQ); 50/54 (92.5%) patients were satisfied with the procedure,

and found it acceptable and similar to expectations. Four patients complained of sensation of a vaginal bulge at 1 year follow-up. In group B, 20 patients complained of vaginal discharge. Four (7.6%) patients had mesh erosions; in 2 women, the portion of eroded mesh was excised, while 2 other patients had small vaginal mesh erosions of approximately 1.5 cm, and were managed conservatively with antibiotics and local oestrogen.

There was no recurrence of cystocele in the mesh group. In the mesh group 48/52 (92%) were satisfied with the procedure, finding it acceptable and similar to what they had expected. Three patients with mesh erosions wished they had undergone traditional repair. One patient had persistent vaginal discharge at the end of 1 year.

Discussion

The current study was performed using a locally designed mesh placement which is a cheaper alternative to trocar-based kits. Also, most of the studies available showed reduced objective recurrence rates of anterior vaginal prolapse with mesh, but the rate of serious complications was high. The available evidence was sparse for definite conclusions.^[8,15,16] This study is the only one in the literature that has used a combination of a vicryl polypropylene mesh, with the hypothesis that the vicryl absorption would enhance the pore size, facilitating take-up and tissue in growth and minimising complications. The use of VYPRO mesh has been evaluated in surgery other than prolapse and the reported erosion rate is 5 - 15%. Also, most literature is from developed nations, and very few randomised controlled trials have been reported from the developing world.

Most of the available literature in recent times has concluded that mesh placement using trocar-based mesh kits or self-designed mesh placement is superior, in terms of reduced recurrence.^[9-14] In contrast, the present study did not show any significant improvement in the anatomical cure rates or reduction in recurrence with the use of mesh in anterior colporrhaphy in comparison with traditional colporrhaphy, although follow-up was limited to 1 year. The use of mesh was associated with significantly increased intraoperative haemorrhage and operating time, which is similar to reports in other studies.^[8,10,16] Reintervention for mesh exposure was 5% in the current

study, which is similar to 3 - 5% as seen in other studies.^[8,10,12,17] There was no new stress urinary incontinence in either of the groups, as is reported by others.^[10,12]

Although standard questionnaires for urinary and sexual functions were not used, a questionnaire validated in the unit showed no significant difference in the satisfaction with and acceptability of the two procedures. Recently the FDA has issued instructions to healthcare providers that in most cases, POP can be treated successfully without mesh, thus avoiding the risk of mesh-related complications.^[13] Also, mesh should be chosen only after weighing the risks and benefits of surgery. Newer complications in association with transvaginal POP repair with mesh, such as mesh contraction, causing vaginal shortening, tightening and/or vaginal pain, are being increasingly reported in the literature.^[13]

Study limitations

The limitations of this study were the small number of patients and the large percentage lost to follow-up. Follow-up was limited to 1 year. The study did not compare the functional outcomes in the two groups, and the questionnaire used to assess satisfaction was validated within the unit. Many procedures were accompanied by other procedures, including McCall's culdoplasty and others.

Conclusion

The effectiveness of use of mesh needs to be validated further, especially for developing countries where use of mesh increases the cost burden to patients and hospitals. More randomised controlled trials are needed to validate routine use of mesh.

1. Beck RP, Nordstrom L. A 25 year experience with 519 anterior colporrhaphy procedures. *Obstet Gynecol* 1991;78(6):1011-1018.
2. Olsen AL, Smith VJ, Bergstrom JO, Colling JC, Clark AL. Epidemiology of surgically managed pelvic organ prolapse and urinary incontinence. *Obstet Gynecol* 1997;89(4):501-506. [[http://dx.doi.org/10.1016/s0029-7844\(97\)00058-6](http://dx.doi.org/10.1016/s0029-7844(97)00058-6)]
3. Hendrix SL, Clark A, Nygaard I, Aragaki A, Barnabei V, McTiernan A. Pelvic organ prolapse in the Women's Health Initiative: Gravity and gravidity. *Am J Obstet Gynecol* 2002;186(6):1160-1166. [<http://dx.doi.org/10.1067/mob.2002.123819>]
4. Weber AM, Walters MD. Anterior vaginal prolapse: Review of anatomy and techniques of surgical repair. *Obstet Gynecol* 1997;89(2):311-318. [[http://dx.doi.org/10.1016/s0029-7844\(96\)00322-5](http://dx.doi.org/10.1016/s0029-7844(96)00322-5)]
5. Shull BL, Capen CV, Riggs MW, Kuehl TJ. Preoperative and postoperative analysis of site-specific pelvic support defects in 81 women treated with sacrospinous ligament suspension and pelvic reconstruction. *Am J Obstet Gynecol* 1992;166(6):1764-1781. [[http://dx.doi.org/10.1016/0002-9378\(92\)91567-t](http://dx.doi.org/10.1016/0002-9378(92)91567-t)]
6. Burger JW, Luijendijk RW, Hop WC, et al. Long term follow up of a randomized controlled trial of suture versus mesh repair of incisional hernia. *Ann Surg* 2004;240(4):578-583. [<http://dx.doi.org/10.1097/01.sla.0000141193.08524.e7>]
7. Julian TM. The efficacy of Marlex mesh in the repair of severe, recurrent vaginal prolapse of the anterior midvaginal wall. *Am J Obstet Gynecol* 1996;175(6):1472-1475. [[http://dx.doi.org/10.1016/s0002-9378\(96\)70092-3](http://dx.doi.org/10.1016/s0002-9378(96)70092-3)]
8. Hiltunen R, Nieminen K, Takala T, et al. Low weight polypropylene mesh for anterior vaginal wall prolapse. *Obstet Gynecol* 2007;110(2):455-462. [<http://dx.doi.org/10.1097/01.aog.0000261899.87638.0a>]
9. Moore RD, Miklos JR. Vaginal mesh kits for pelvic organ prolapse. *Sci World J* 2009;9(3):163-189. [<http://dx.doi.org/10.1100/tsw.2009.19>]
10. Altman D, Väyrynen T, Engh ME, Axelsen S, Falconer C. Anterior colporrhaphy versus transvaginal mesh for pelvic-organ prolapse. *N Engl J Med* 2011;364(19):1826-1836. [<http://dx.doi.org/10.1056/NEJMoa1009521>]
11. Grgic O, Oreskovic S, Grsic HL, Kalafatic D, Zupic T, Maurac I. Outcome and efficacy of a transobturator polypropylene mesh kit in the treatment of anterior pelvic organ prolapse. *Int J Gynecol Obstet* 2012;116(1):72-75. [<http://dx.doi.org/10.1016/j.ijgo.2011.08.014>]
12. Nieminen K, Hiltunen R, Takala T, et al. Outcomes after anterior vaginal wall repair with mesh: A randomized, controlled trial with a 3 year follow-up. *Am J Obstet Gynecol* 2010;203(3):235.e1-e8. [<http://dx.doi.org/10.1016/j.ajog.2010.03.030>]
13. <http://www.fda.gov/MedicalDevices/ProductsandMedicalProcedures/ImplantsandProsthetics/UroGynSurgicalMesh/ucm262299.htm> (accessed 5 September 2013).
14. Bump RC, Mattiasson A, Bo K, et al. The standardization of terminology of female pelvic organ prolapse and pelvic floor dysfunction. *Am J Obstet Gynecol* 1996;175(1):10-17. [[http://dx.doi.org/10.1016/s0002-9378\(96\)70243-0](http://dx.doi.org/10.1016/s0002-9378(96)70243-0)]
15. Jia X, Glazener C, Mowatt G, MacLennan G, Bain C, Fraser C, Burr J. Efficacy and safety of using mesh or grafts in surgery for anterior and/or posterior vaginal wall prolapse: Systematic review and meta-analysis. *BJOG* 2008;115(11):1350-1361. [<http://dx.doi.org/10.1111/j.1471-0528.2008.01845.x>]
16. Nguyen JN, Burchette RJ. Outcome after anterior vaginal prolapse repair: A randomized controlled trial. *Obstet Gynecol* 2008;111(4):891-898. [<http://dx.doi.org/10.1097/AOG.0b013e31816a2489>]
17. Muffly TM, Barber MD. Insertion and removal of vaginal mesh for pelvic organ prolapse. *Clin Obstet Gynecol* 2010;53(1):99-114. [<http://dx.doi.org/10.1097/GRF.0b013e3181cefab8>]