

CASE REPORT

Conservative management of cervical ectopic pregnancy



T D Naidoo, MB ChB, FCOG

M R Ramogale, MB ChB

J Moodley, MB ChB, FCOG, FRCOG, MD

Department of Obstetrics and Gynaecology and MRC/UN Pregnancy Hypertension Research Unit, Nelson R Mandela School of Medicine, University of KwaZulu-Natal, Durban

The increasing incidence of cervical pregnancies may be attributed to increased use of artificial reproductive techniques and diagnostic improvements. Historically surgery has been the mainstay of treatment, usually with a poor prognosis. Recently there has been a trend toward conservative management with improved prognosis. Spontaneous abortion of a cervical pregnancy is usually associated with profuse haemorrhage or sepsis. A case undergoing spontaneous abortion without any life-threatening sequelae is presented.

Case report

A 31-year-old primigravida was admitted to a district hospital with a 7-week history of amenorrhoea, lower abdominal pain and minimal vaginal bleeding of 1 day's duration. She was haemodynamically stable and her abdomen was soft, moved with respiration and no pelvic masses were palpable. Speculum examination revealed a barrel-shaped, oedematous and enlarged cervix (the size of a tennis ball), which was closed.

The serum beta-human chorionic gonadotrophin (β -HCG) was 6 307 IU/ml, the haemoglobin concentration 11.9 g/dl, the platelet count $286 \times 10^9/\mu\text{l}$ and the white cell count $5.9 \times 10^9/\mu\text{l}$. A pelvic ultrasound scan revealed no intrauterine pregnancy and confirmed a cervical ectopic pregnancy of 7 weeks' gestation. Magnetic resonance imaging (MRI) scans showed a cervical ectopic pregnancy and posterior uterine fibroid (Fig. 1).

Medical management with methotrexate followed later by uterine artery embolisation was decided on and informed consent obtained.

However, before commencement of treatment the patient reported passing clots, and a repeat ultrasound examination showed no evidence of a gestational sac. The patient remained stable and by 48 hours after passing the gestational sac the serum β -HCG had fallen to 3 392 IU/ml: it declined further to 2 828 IU/ml on day 5 and 1 490 IU/ml on day 7.

On discharge the β -HCG was 1 380 IU/ml, becoming negative a month later. On follow-up 6 months later the serum β -HCG remained negative.

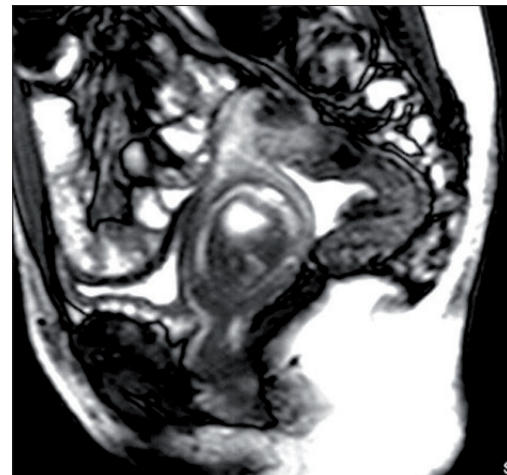


Fig. 1. Cervical ectopic pregnancy.

Discussion

Cervical pregnancy is rare and extremely dangerous, with an incidence ranging from 1:1 000 to 1:18 000 pregnancies.¹ The incidence appears to be rising as a result of increasing use of assisted reproduction techniques.²

Controversy still abounds with regard to the diagnosis of cervical pregnancy, which was first described by Rubin in 1911. Surgical, pathological, clinical and/or ultrasound criteria may be used. More recently ultrasound has become the mainstay of diagnosis.³ Hoffmann *et al.*⁴ proposed that the diagnostic criteria of cervical pregnancy should be: (i) absence of intrauterine pregnancy; (ii) a distended cervix; (iii) an hourglass-shaped uterus; and (vi) the presence of conceptual or placental tissue within the cervix.⁴

MRI and transvaginal colour Doppler have been shown to improve the diagnosis.⁵

The cause of cervical implantation is unclear, but any factor leading to a decrease in the likelihood of normal endometrial implantation may increase the risk.³ Analysis of 102 cases of cervical pregnancy revealed that approximately 70% of patients had a history of previous uterine curettage.⁶

Previously, about half of all cervical pregnancies were managed surgically by abdominal hysterectomy, but newer techniques have been utilised in an attempt to prevent radical surgery. Conservative measures have therefore become 'first-line management'.

A review of the literature suggests that a conservative approach seems defensible, with the management options including: leaving the placenta *in situ*, curettage and tamponade, cervical amputation, cervical cerclage, ligation of uterine or internal iliac arteries, angiographic uterine artery embolisation, and systemic or intra-amniotic administration of methotrexate.⁶

While there is documentation in the literature of women with cervical pregnancies undergoing spontaneous abortion, these are usually associated with profuse haemorrhage from the site of implantation.⁴ The case presented here is the first recorded case of spontaneous abortion without severe haemorrhage. The presence of a posterior fibroid may have contributed to initial implantation in the cervix.

1. Urbani G, Cronje HS. Cervical pregnancy in an HIV-infected patient treated by uterine artery embolisation and methotrexate. *S Afr Med J* 2003; **93**: 776-777.
2. Olah KS. Massive obstetric haemorrhage resulting from a conservatively managed cervical pregnancy at delivery of its twin. *Br J Obstet Gynaecol* 2003; **110**: 956-957.
3. Yankowitz J, Leake J, Huggins G, Gazaway P, Gates E. Cervical ectopic pregnancy: Review of the literature and report of a case treated by single-dose methotrexate therapy. *Obstet Gynecol Surv* 1990; **45**: 405-412.
4. Hoffmann HM, Urdl W, Hofler H, et al. Cervical pregnancy: Case reports and current concepts in diagnosis and treatment. *Arch Gynecol Obstet* 1987; **241**: 63-69.
5. Seow KM, Hwang JL, Tsai YL, Lin YH, Hsieh BC, Huang SC. Transvaginal colour Doppler diagnosis and assessment of a heterotopic cervical pregnancy terminated by forceps evacuation following *in vitro* fertilization and embryo transfer. *Br J Obstet Gynaecol* 2002; **109**: 1072-1073.
6. Marcovici I, Rosenzweig BA, Brill AI, Khan M, Scommegna A. Cervical pregnancy: case reports and a current literature review. *Obstet Gynecol Surv* 1994; **49**: 49-54.