

Medi Challenge confirms its commitment to provide safe and effective support to women throughout all phases of their lives. We are proud to announce extended approved indications and routes of administration.



STANDING BY WOMEN FROM FERTILITY THROUGH MATERNITY INTO MENOPAUSE

Indications: ¹

In addition to its use for Hormone Replacement Therapy in menopause (oral) we have obtained the following indications for vaginal administration:

- Threatened early miscarriage or repeated miscarriage due to luteal phase insufficiency
- Progesterone replacement therapy in cases of ovarian insufficiency or complete ovarian failure
- Supplementation of the luteal phase in cases of spontaneous or induced cycles, or primary or secondary sterility, particularly due to dysovulation
- Supplementation of the luteal phase during IVF cycles

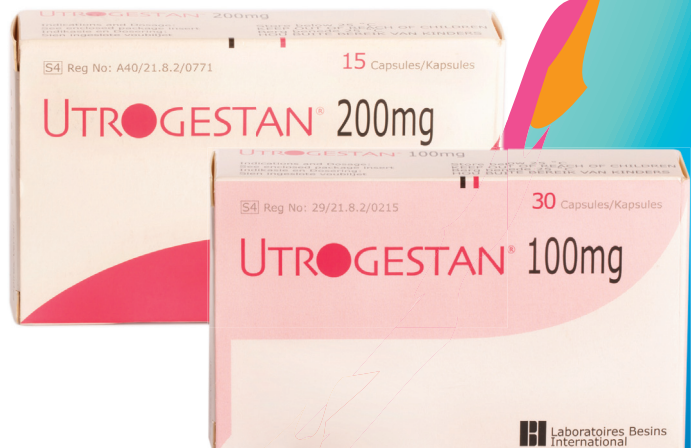Pharmacokinetic properties: ¹

- **UTROGESTAN**® is to be inserted deep into the vagina
- **UTROGESTAN**® is rapidly absorbed by the vaginal mucosa following vaginal insertion
- **UTROGESTAN**® acts on the endometrium by converting the proliferating phase to the secretory
- Maximum plasma concentration is reached two to six hours after administration and remains stable at physiological concentrations similar to those observed during the luteal phase of normal ovulatory menstrual cycle or those described during the first trimester of pregnancy subject to the indication and the dosage regime

Product	Nappi Code	Medicine Schedule	Active ingredient	Strength	Dosage Form	Quantity
UTROGESTAN	851957-005	S4	Micronised progesterone	100 mg	Capsules	30
UTROGESTAN	717195-001	S4	Micronised progesterone	200 mg	Capsules	15

References: 1. **UTROGESTAN**® PI

For more information on **UTROGESTAN**®
or to obtain full Product Information
please contact Medical Department at
denitza@medichallenge.co.za.



MEDI CHALLENGE (PTY) LTD
Innovating for Well-being **BESINS HEALTHCARE**

MEDI CHALLENGE (PTY) LTD
Fancourt Office Park,
North Riding, Johannesburg.
www.medichallenge.co.za

Reg. No: 29/21.8.2/0215; A40/21.8.2/0771

Bicornuate uterus with second trimester fetal demise in a rudimentary horn

R Nelson, MB ChB

Department of Obstetrics and Gynaecology, Faculty of Health Sciences, University of the Witwatersrand, Johannesburg, South Africa

Corresponding author: R Nelson (ronwynnelson@gmail.com)

Bicornuate uterus is a congenital uterine anomaly associated with reproductive complications such as recurrent pregnancy loss, preterm birth, cervical insufficiency and uterine rupture. A bicornuate uterus occurs owing to failure of septal resorption after fusion of the paramesonephric ducts during organogenesis, resulting in a uterus divided into two horns. Most cases are only identified once reproductive difficulty is experienced or as an incidental finding in patients with a normal obstetric history. Here we present a patient who had two previous normal vaginal deliveries at term who was incidentally found to have a bicornuate uterus with second trimester fetal demise in the rudimentary horn. A hysterotomy and bilateral tubal ligation was performed, and the patient was discharged in good health after 48 hours.

S Afr J Obstet Gynaecol 2022;28(1). <https://doi.org/10.7196/SAJOG.2022.v28i1.2054>

The female reproductive system develops between the 6th and 12th week of gestation. Two pairs of genital ducts arise from the intermediate mesoderm layer of the embryo – the mesonephric (Wolffian duct) and paramesonephric (Mullerian duct). From week 6 of gestation, regression of the Wolffian duct and further development of the Mullerian ducts occur due to absence of the anti-Mullerian hormone and *SRY* gene. The uterus, fallopian tubes, cervix and upper third of the vagina arise from two pairs of Mullerian ducts. During the 8th week of gestation, the Mullerian ducts fuse cranially to form the uterus and caudally to form the upper third of the vagina. A midline septum is present, which usually reabsorbs around 20 weeks of gestation.^[1]

Normal development of the female reproductive system forms in three phases – organogenesis, fusion and septal resorption. Defects during these phases result in Mullerian duct anomalies (MDA), which are classified into seven classes: class I (uterine agenesis); class II (unicornuate uterus); class III (uterine didelphys); class IV (bicornuate uterus); class V (sub-septate uterus); class VI (arcuate uterus); and class VII (septate/T-shaped uterus). The incidence of bicornuate uterus is 25%.^[2]

In the present report, a patient with an incidental finding of bicornuate uterus with the pregnancy in the rudimentary horn was identified. Pregnancy in a rudimentary horn is rare and incidence is around 1/400 000.^[3] Bicornuate uterus is associated with multiple complications such as infertility, recurrent pregnancy loss, prematurity, cervical incompetence, chronic pelvic pain, abnormal uterine bleeding, and uterine rupture.^[4]

Case

A 44-year-old female presented to the Obstetrics and Gynaecology antenatal outpatients department of Charlotte Maxeke Johannesburg Academic Hospital. The patient was referred as a high-risk pregnancy owing to advanced maternal age. History included two previous uncomplicated normal vaginal deliveries in 1995 and 2005, and a first trimester miscarriage in 2018. On the first

visit, ultrasonography of the abdomen and pelvis identified a live intrauterine pregnancy at 16 weeks' gestation with what appeared to be a 'fibroid-like' structure in the lower segment of the uterus measuring 5.7 × 5.8 cm. The patient was diagnosed with a fibroid uterus in pregnancy and advanced maternal age; follow-up was scheduled in 4 weeks.

During the next visit in the antenatal outpatient's department, ultrasonography revealed an intrauterine fetal demise at 21 weeks of gestation with a fibroid identified in the lower segment of the uterus. The patient was counselled and admitted for induction of labour with vaginal misoprostol.

After five doses of misoprostol (200 µg), there were no signs of uterine contraction or cervical dilatation. A second attempt at induction was performed by inserting a mechanical catheter bulb, which also had no effect on uterine contraction or cervical dilatation. Explanation of the lack of uterine response was thought to be due to the 'fibroid' obstructing the lower segment, which may have been preventing uterine contraction. The patient was thus booked for hysterotomy for failed induction of labour owing to fibroid uterus, and intrauterine fetal demise at 21 weeks' gestation.

A bicornuate uterus was identified intraoperatively. The failed pregnancy was positioned in the rudimentary horn of the uterus on the left side. Each uterine horn possessed its own round ligament, fallopian tube, and ovary that looked normal in structure. A classical incision was performed to deliver the fetus from the rudimentary horn (Fig. 1). The rudimentary horn was sutured, and bilateral tubal ligation was performed.

Discussion

A bicornuate uterus is classified as a class IV MDA. It is a congenital uterine anomaly that occurs due to a defect in septal resorption after fusion of the paramesonephric ducts, resulting in a uterus divided into two horns. Congenital uterine anomalies occur in 1.5% of females and bicornuate uteri represent about 25% of MDAs.^[2]

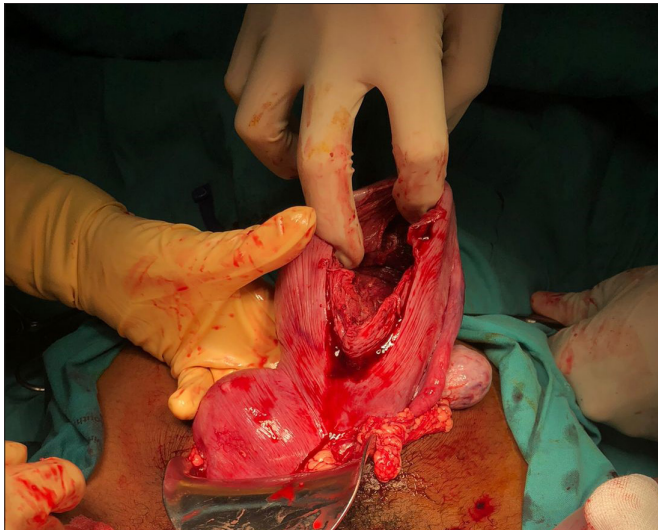


Fig. 1. Photograph of bicornuate uterus - surgeon holding uterus, with non-communicating rudimentary horn attached to left side of uterus. A classic hysterotomy incision was made on the rudimentary horn. (Post-delivery image of a 21-week macerated fetus and placenta.)

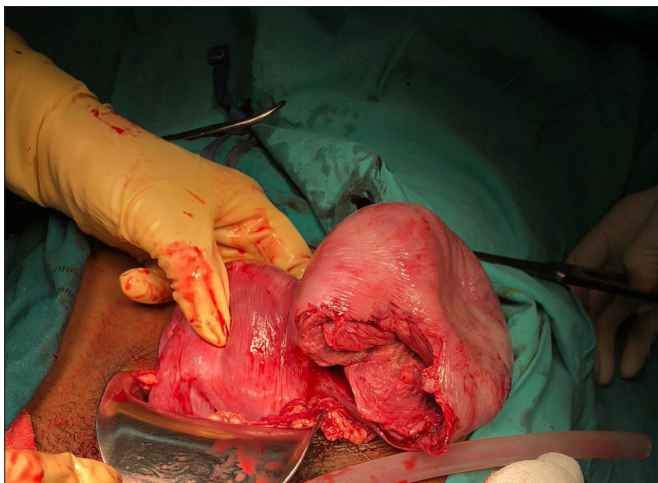


Fig. 2. Photograph of bicornuate uterus, displaying the cavity of the non-communicating rudimentary horn where a 21-week macerated fetus and placenta were delivered. The left fallopian tube and ovary are attached to the left border of rudimentary horn, and the right fallopian tube and ovary are attached to right border of uterus.

Clinical presentation

In most cases, a bicornuate uterus is an incidental finding and may reach full-term delivery. Successful delivery of a twin pregnancy in a bicornuate uterus has been documented.^[5]

Pregnancy in a bicornuate uterus is considered high-risk and requires extra monitoring because of risk of poor obstetric outcome. The most common symptomatic presentation and complications include recurrent pregnancy loss (25%),^[6] preterm birth (15 - 25%),^[7] cervical insufficiency (38%),^[8] malpresentation, intrauterine growth restriction and antepartum haemorrhage. Infertility is not usually a problem with this type of malformation because ovulation and implantation of the embryo is not impaired.

If the pregnancy is implanted in a well-developed horn, it usually continues normally and can develop into a full-term fetus. However, danger needs to be anticipated if a pregnancy is identified

in the rudimentary horn as complications are more likely to occur. Pregnancy in the rudimentary horn is rare and is reported in both communicating and non-communicating horns.^[9] The present case involved a pregnancy implanted in a non-communicating rudimentary horn and resulted in early fetal demise and subsequent hysterotomy.

Subtypes

A bicornuate uterus is divided according to the involvement of the cervical canal as either bicornuate bicollis (two cervical canals, central myometrium extends to the external cervical os) or bicornuate unicollis (one cervical canal, central myometrium extends to the internal cervical os).

Radiographical features and diagnosis

The preferred methods of imaging for uterine anomalies are ultrasound, hysterosalpingogram (HSG) or magnetic resonance imaging (MRI). HSG is used as first-line investigation of tubal pathology and is not as sensitive at detecting intrauterine abnormalities. Limitations of HSG include difficulty in differentiating between the various duplication anomalies and identifying non-communicating rudimentary cornua. Instillation of a large amount of contrast medium into the uterine cavity can also obscure the presence of small uterine septa. Other methods such as hysteroscopy may be more effective. Three-dimensional ultrasound is also useful as both the external contours and internal morphology of the uterus may be displayed on the coronal plane, and the presence and type of uterine anomaly may be accurately detected. In the bicornuate uterus, the external uterine contour is heart-shaped and the uterine horns are widely divergent. The uterus appears as caudally fused symmetric uterine cavities with some degree of communication between the two cavities. The round ligament, fallopian tube and ovary are connected to each horn.^[10] The gold standard methods for diagnosis are hysteroscopy and laparoscopy.

Treatment and prognosis

Surgical intervention is usually only indicated in the incidence of reproductive difficulties.

The standard surgical procedure for correction of bicornuate uteri is Strassman metroplasty. Paul Strassman reported the first surgical correction for the double uterus in 1907 by performing an anterior colpotomy in a patient with eight pregnancy losses.^[11] Open or laparoscopic metroplasty can be performed by making a fundal transverse incision and dissection to the level of the endometrium after injection of subserosal vasopressin, followed by apposition of the two horns and suturing of the uterus in layers. Strassman metroplasty is mostly considered in women with a history of recurrent pregnancy loss.^[12]

The present patient was advanced in maternal age and had two live children, therefore opted for bilateral tubal ligation. Strassman metroplasty was not indicated.

In cases of cervical incompetence, cervical cerclage may increase fetal survival rates. Prophylactic cerclage may even be appropriate as the association between bicornuate uterus and cervical incompetence is so high.^[2]

Rupture in a rudimentary horn pregnancy can occur owing to inability of the malformed uterus to expand with increasing gestational age and is likely to occur late first trimester. In the event of rudimentary horn rupture, the entire horn should be excised.^[13]

Differential diagnosis

Differentials to bicornuate uterus include uterus didelphys (complete failure of fusion of paramesonephric ducts, resulting in duplication of the uterus, cervix and vagina) and septate uterus (persistent longitudinal septum that partially divides the uterine cavity).^[12]

Conclusion

The present case highlights the possibility of misdiagnosing a malformed uterus. Congenital uterine anomalies should always be kept in mind when ultrasonography is unclear and further investigations should be performed to reach the correct diagnosis. Bicornuate uterus is rare and may result in uncomplicated pregnancies; however, complications such as uterine rupture can be catastrophic, and in such instances, early diagnosis and management is crucial.

Declaration. None.

Acknowledgements. We are deeply grateful to the patient who gave her consent to produce this report.

Author contributions. RN conceptualised the study, looked after the patient, and wrote and revised the manuscript.

Funding. None.

Conflicts of interest. None.

1. Robbins JB, Broadwell C, Chow LC, Parry JP, Sadowski EA. Müllerian duct anomalies: Embryological development, classification, and MRI assessment. *J Magn Reson Imaging* 2015;41(1):1-12. <https://doi.org/10.1002/jmri.24771>.
2. Nahum GG. Uterine anomalies. How common are they, and what is their distribution among subtypes? *J Reprod Med* 1998;43(10):877-887.
3. Strassmann EO. Fertility and unification of double uterus. *Fertil Steril* 1966;17:165-176. [https://doi.org/10.1016/s0015-0282\(16\)35882-4](https://doi.org/10.1016/s0015-0282(16)35882-4).
4. Raga F, Bauset C, Remohi J, Musoles FB, Simon C. Reproductive impact of congenital Mullerian anomalies. *Hum Reprod* 1997;12:2277-2281. <https://doi.org/10.1093/humrep/12.10.2277>
5. Cruceyra M, Iglesias C, De La Calle M, Sancha M, Magallon SL, Gonzalez A. Successful delivery of a twin pregnancy in a bicornuate uterus (uterus bicornis unicollis) by bilateral caesarean section. *J Obstet Gynaecol Can* 2011;33:142-144. <https://doi.org/10.5935/1518-0557.20200019>
6. Lin PC. Reproductive outcomes in women with uterine anomalies. *J Womens Health (Larchmt)* 2004;13:33-39. <https://doi.org/10.1089/154099904322836438>
7. Heinonen PK, Saarikoski S, Pystynen P. Reproductive performance of women with uterine anomalies. An evaluation of 182 cases. *Acta Obstet Gynaecol Scand* 1982;61:157-162. <https://doi.org/10.3109/00016348209156548>
8. Golan A, Langer R, Wexler S, Segev E, Niv D, David MP. Cervical cerclage – its role in the pregnant anomalous uterus. *Int J Fertil* 1990;35:164-170.
9. Whitehouse B. Rupture of pregnant rudimentary horn of bicornate uterus. *Proc R Soc Med* 1912;5:121-124.
10. Ly JQ. Rare bicornuate uterus with fibroid tumors: Hysterosalpingography-MR imaging correlation. *AJR Am J Roentgenol* 2002;179(2):537-538. <https://doi.org/10.2214/ajr.179.2.1790537>
11. Strassmann E. Plastic unification of double uterus; a study of 123 collected and five personal cases. *Am J Obstet Gynecol* 1952;64(1):25-37. [https://doi.org/10.1016/s0002-9378\(16\)38732-4](https://doi.org/10.1016/s0002-9378(16)38732-4)
12. Tomasz R, Marta M, Aleksandra B. Clinical effectiveness of Strassman operation in the treatment of bicornuate uterus. *Ginekologia Polska* 2009;80(2):88-92.
13. Chaudhry S. AJR teaching file: Infertility in a young woman. *AJR Am J Roentgenol* 2007;189(3):S11-S12. <https://doi.org/10.2214/AJR.07.7019>
14. Chang JC, Lin YC. Rupture of rudimentary horn pregnancy. *Acta Obstet Gynaecol Scand* 1992;71:235-238. <https://doi.org/10.3109/00016349209009926>

Accepted 11 January 2022.