

# Beckwith-Wiedemann syndrome associated with congenital cytomegalovirus in an HIV-exposed neonate

**K E Sprong**<sup>1</sup>, BSc, BSc (Hons), MSc; **C A Wright**<sup>2,3</sup>, MB BCh, MMed, FCPATH, FRCPath, FIAC, PhD;  
**M Mabenge**,<sup>4</sup> BSc, MB ChB, Dip Obst, MMed (O&G), FCOG, Cert Gynae Onc; **S Govender**,<sup>1</sup> BSc, BSc (Hons), MSc, PhD

<sup>1</sup> Department of Biochemistry and Microbiology, Nelson Mandela University, Port Elizabeth, South Africa

<sup>2</sup> Lancet Laboratories, Johannesburg, South Africa

<sup>3</sup> Division of Anatomical Pathology, Department of Pathology, University of Stellenbosch, Cape Town, South Africa

<sup>4</sup> Department of Obstetrics and Gynaecology, Dora Nginza Hospital, Walter Sisulu University, Port Elizabeth, South Africa

**Corresponding author:** S Govender ([sharlene.govender@mandela.ac.za](mailto:sharlene.govender@mandela.ac.za))

Congenital cytomegalovirus (CMV) infection is associated with preterm birth and congenital abnormalities, which could be exacerbated by maternal co-infection with HIV. This case report describes an HIV-exposed neonate with Beckwith-Wiedemann syndrome (BWS), born by a mother who had a CMV infection of the placenta, who demised following laparoscopic repair of an omphalocele.

*S Afr J Obstet Gynaecol* 2020;26(2):79-81. <https://doi.org/10.7196/SAJOG.2020.v26i2.1595>

Cytomegalovirus (CMV) is a common DNA virus that belongs to the herpes family and is able to infect people of all ages. Babies born with the infection acquired *in utero* are said to have congenital cytomegalovirus (CMV) infection. Infection with CMV may be asymptomatic or present with symptoms that are severe and life-threatening.<sup>[1]</sup> Pregnancy does not appear to affect the clinical severity of CMV disease; however, the integrity of the host immune system affects the spectrum of the disease. Hosts with impaired cellular immune systems such as in pregnancy and other immunosuppressive illnesses are at a risk of severe and disseminated infection. Primary infection, reactivation, reinfection and quiescence are difficult to distinguish by serological diagnosis, as all these infections are associated with IgM and IgG. Determination of IgG avidity is essential for the acuity of the infection and *in utero* transmission. Primary CMV infection may occur during pregnancy and serology will reveal positive IgG and IgM with a low avidity of IgG, while non-primary infection occurring before pregnancy is characterised by maternal CMV antibodies prior pregnancy.<sup>[1]</sup>

Maternal viraemia leads to cytotrophoblast infection with the resultant transplacental infection of the fetus. CMV is associated with adverse pregnancy outcomes including preterm birth, spontaneous miscarriage, stillbirth and microcephalus.<sup>[2]</sup> Intestinal involvement in CMV-infected neonates may be more common than previously considered, with reports of inflammatory bowel disease, volvulus, diarrhoea, gastroenteritis, colitis, necrotising enterocolitis and perforation or strictures at the terminal stage of the inflammatory progression.<sup>[3]</sup> Women who are HIV-positive may experience CMV reactivation with advancing immune impairment. Maternal co-infection with HIV and CMV increases the rate of vertical transmission of congenital CMV and accelerates the progression of HIV in exposed infants.<sup>[1]</sup>

Beckwith-Wiedemann syndrome (BWS) is a genomic imprinting disorder characterised by a spectrum of clinical features including overgrowth, macroglossia, abdominal wall defects such as omphalocele, neonatal hypoglycaemia and an increased risk of

developing embryonal tumours in childhood. The cause of BWS is complex but involves genes that control growth located on chromosome 11. Diagnosis may be based on clinical characteristics and confirmed by genetic testing; however, molecular confirmation is susceptible to tissue mosaicism and warrants testing from multiple tissues for confirmation.<sup>[4]</sup>

In this report, we describe a case of neonatal death following laparoscopic repair of an omphalocele in BWS, with bowel perforation and septicaemia from an HIV-infected mother with CMV infection of the placenta. Due to the high frequency of HIV in South Africa (SA) and associated risk of CMV infection, more attention should be given to management of CMV-infection-related poor pregnancy/neonatal outcomes.

## Case report

A 37-year-old pregnant female was admitted to a provincial tertiary hospital in Port Elizabeth, SA, after presenting with spontaneous preterm labour with complications at 33 weeks. The patient consented to participate in this study and granted permission for access to medical records of both mother and neonate for which ethical approval was obtained from the Nelson Mandela University Human Research Ethics Committee (ref. no. H15-SCI-BCM-001) and permission to conduct the study was obtained from the Eastern Cape Department of Health (ref. no. EC\_2015RP8\_78). She was a gravida 2, para 2 mother and had previously been diagnosed with HIV (CD4 count 324 cells/ $\mu$ L and taking fixed dose combination antiretroviral (ARV) drugs). There were no further risk factors. She was in active labour during admission and ultrasound identified polyhydramnios and an omphalocele. This led to the indication of delivery by caesarean section in order to reduce pressure on the exposed fetal organs. A male baby weighing 2 300 g was born by caesarean section at 33 weeks' gestation. Following delivery, the neonatal Apgar scores at 1 and 5 minutes were 6 and 8, respectively, and blood pressure was 56/26 mmHg with a pulse of 140 bpm.

Macroscopic examination of the placenta revealed a weight of 371 g, dimensions 180 × 150 × 20 mm with normal cord insertion and no meconium present (Fig. 1A). The umbilical cord was 640 mm in length, 12 mm in diameter, trivascular with 10 coils and one obstructive knot. The maternal surface of the placenta was complete with ~5% retroplacental blood clot. Histopathology findings were available (within 3 - 4 days after delivery) before the second surgical procedure and revealed the presence of increased syncytial knots, focal avascular villi and diffuse calcification (Fig. 1B). In addition, there was multifocal chronic villitis with plasma cells, positive on immunohistochemistry for CMV (Fig. 1C). Overall diagnosis of the placental histology was maternal vascular malperfusion and chronic villitis due to CMV.

The neonate showed signs of intrauterine growth restriction and the omphalocele had an intact membrane. It was determined that the neonate was exposed to HIV from the mother and was administered nevirapine as per the policy in the hospital neonatal unit. The neonate presented with a large mouth, protruding tongue and omphalocele clinically indicative of Beckwith-Wiedemann syndrome. A laparoscopic repair was performed on the omphalocele on day 1 of life and the neonate was monitored post-operatively. Intestinal congenital atresia was suspected for which a second laparotomy was performed on day 7 at which findings were a suspected non-benign renal lesion, consistent with BWS. The renal lesion was not biopsied as the neonate was too ill for investigations. Post surgery the neonate developed malrotation of the bowel, aganglionosis, an enlarged bladder, sepsis and apnoeic spells and was intubated but demised 12 days after delivery.

## Discussion

BWS is a paediatric overgrowth disorder involving a predisposition to tumour development and has highly variable presentation. The syndrome is often diagnosed postnatally or in early childhood and has a broad clinical spectrum of features that vary in severity. Prenatal molecular diagnosis of BWS is possible in some cases; however, due to tissue mosaicism and possible maternal contamination, testing is usually indicated postnatal in conjunction with clinical features.<sup>[4]</sup> Delineation of the molecular defects within the imprinted chromosome 11p15.5 region can predict familial recurrence risks, and the risk and type of embryonal tumour. Despite recent advances in knowledge,

there is marked heterogeneity in clinical diagnostic criteria and care. CMV can lead to congenital infections through transplacental transmission and is one of the most common intrauterine viral infections in pregnancy. There is a higher prevalence of CMV in developing countries and with low socioeconomic status. Manicklal *et al.*<sup>[5]</sup> reported that congenital CMV had a prevalence of 2.9% and was associated with advanced maternal immunosuppression despite prenatal ARV drugs prophylaxis in the Western Cape region of SA. A higher prevalence of congenital CMV (5.96%) was reported by Tshabalala *et al.*<sup>[6]</sup> in the Eastern Cape Province, SA, but the study found no significant association between congenital CMV and maternal HIV infection. Although our case was asymptomatic with a low viral load, maternal CMV and HIV infection should be considered a high-risk factor for adverse pregnancy outcomes, possible neonatal congenital abnormalities and long-term adverse infant sequelae. It is vital to assess placentas from HIV-infected high-risk mothers, especially in cases where routine screening for infections including CMV are not performed.

Many patients present late in pregnancy in SA and are never scanned or only have a single early pregnancy scan. Therefore, markers of CMV infection such as microcephaly would be unrecognised in the majority of pregnancies. The cost of comprehensive antenatal diagnosis and treatment of CMV infection is impractical in the SA context and there is a need for more affordable solutions. There is limited evidence of the benefit of antenatal antiviral therapy and it is seldom considered during pregnancy due to its toxicity.<sup>[7]</sup>

Perinatal ultrasound can assist in identifying growth abnormalities or amniotic fluid volume abnormalities that may suggest symptomatic fetal infection.<sup>[2]</sup> As CMV is ubiquitous in adults in SA, this may represent colonisation of the neonate during birth. Only microcephaly, which occurs in a minority of cases, may be recognised. There would be assessment of possible cognitive impairment if detection of microcephaly, intracranial calcifications and abnormal computed tomography scan findings occurs in the first month of life. In the present case, the mother was neither aware of her CMV infection nor the congenital malformation of her neonate prior to hospitalisation for premature labour, where an ultrasound alerted the doctors to the fetal omphalocele.

Animal models and clinical reports suggest that CMV may increase intestinal mucosal permeability, therefore predisposing to bacterial

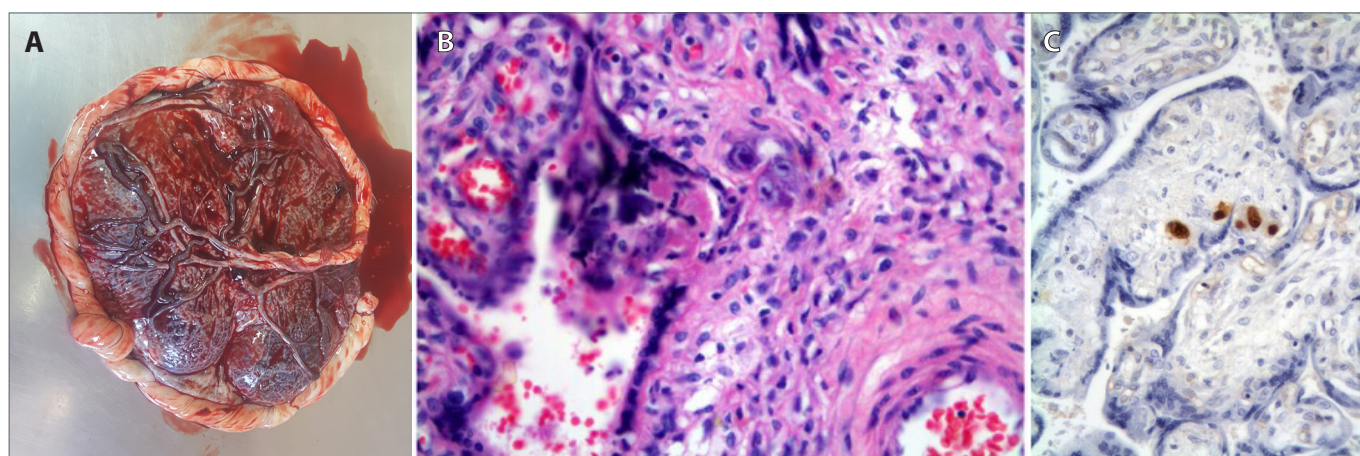


Fig. 1. (A) Macroscopic view of the placenta post-delivery. (B) The histologic appearance of placental villi showing chronic villitis and endothelial cells with basophilic intranuclear inclusions. Placental tissue was stained with haematoxylin and eosin (H&E) and viewed under a light microscopy (1 000× magnification). (C) Positive immunohistochemistry for cytomegalovirus.

invasion. CMV may also exacerbate the intestinal immune response thereby enhancing production of proinflammatory mediators. In premature infants, who have both an underdeveloped gut barrier function and immature immune responses, CMV infections increase the risk of developing necrotising enterocolitis.<sup>[8]</sup> In the present case, CMV may have predisposed the intestinal post-laparoscopic repair to nosocomial infection in an already compromised neonate; however, autopsy data were not available to conclusively indicate CMV infection in the intestine and the poor outcome may or may not be due to CMV.

Congenital CMV infection remains an important cause of neonatal morbidity and mortality and affects those who are symptomatic and asymptomatic at birth. Ganciclovir treatment is advised only if the neonate is symptomatic clinically and is effective in reducing hearing loss and retinitis. However, it causes side-effects on a susceptible premature neonate that include neutropaenia and toxicity. Valganciclovir has also been reported to provide effective reduction of hearing loss and improvement in development of those treated at birth.<sup>[9]</sup>

## Conclusion

Despite the prevalence and clinical importance of CMV, there is limited awareness about the clinical outcomes, epidemiology and risk factors associated with maternal CMV infection during pregnancy and congenital CMV infection when associated with other risk factors such as maternal HIV infection and BWS. This should be swiftly remedied especially in areas of high prevalence of HIV infection and maternal HIV-CMV co-infection.

**Declaration.** This study was done in partial fulfilment of requirements of a PhD degree.

**Acknowledgments.** None.

**Author contributions.** All authors contributed equally to writing and review of the manuscript.

**Funding.** The research was supported by a grant from the National Health Laboratory Services Research Trust.

**Conflicts of interest.** None.

1. Manicklal S, Emery VC, Lazzarotto T, et al. The 'silent' global burden of congenital cytomegalovirus. *Clin Microbiol Rev* 2013;26(1):86-102. <https://doi.org/10.1128/CMR.00062-12>.
2. van Zuylen WJ, Hamilton ST, Naing Z, et al. Congenital cytomegalovirus infection: Clinical presentation, epidemiology, diagnosis and prevention. *Obstet Med* 2014;7(4):140-146. <https://doi.org/10.1177/1753495X14552719>
3. Goelz R, Hamprecht K, Klingel K, et al. Intestinal manifestations of postnatal and congenital cytomegalovirus infection in term and preterm infants. *J Clin Virol* 2016;83:29-36. <https://doi.org/10.1016/j.jcv.2016.08.289>.
4. Wang KH, Kupa J, Duffy KA, et al. Diagnosis and management of Beckwith-Wiedemann syndrome. *Front Pediatr* 2020;7:562. <https://doi.org/10.3389/fped.2019.00562>.
5. Manicklal S, van Niekerk AM, Kroon SM, et al. Birth prevalence of congenital cytomegalovirus among infants of HIV-infected women on prenatal antiretroviral prophylaxis in South Africa. *Clin Infect Dis* 2014;58(10):1467-1472. <https://doi.org/10.1093/cid/ciu096>.
6. Tshabalala D, Newman H, Businge C, et al. Prevalence and determinants of congenital cytomegalovirus infection at a rural South African central hospital in the Eastern Cape. *S Afr J Infect Dis* 2018;33(4):89-92. <https://doi.org/10.1080/23120053.2018.1462560>.
7. Van der Colf BE, van Zyl GU, Mackenzie SBP. Seroprevalence of cytomegalovirus among pregnant women in Windhoek, Namibia, 2016. *S Afr J Obstet Gynaecol* 2019;25(2):52-55. <https://doi.org/10.7196/SAJOG.2019.v25i2.1441>
8. Berardi A, Spaggiari E, Cattelani C, et al. Persistent intestinal bleeding due to severe CMV-related thrombocytopenia in a preterm newborn. *J Matern Fetal Neonatal Med* 2018;31(9):1246-1249. <https://doi.org/10.1080/14767058.2017.1312331>.
9. Nassetta L, Kimberlin D, Whitley R. Treatment of congenital cytomegalovirus infection: Implications for future therapeutic strategies. *J Antimicrob Chemother* 2009;63(5): 862-867. <https://doi.org/10.1093/jac/dkp083>.

Accepted 25 November 2020.