

Reduction of subacute uterine inversion by Haultain's method: A case report

E Ziki,¹ MB ChB, MMed; S Madombi,¹ MB ChB; C Chidhakwa,¹ FCOG; M G Madziyire,¹ MMed; N Zakazaka,² MMed

¹ Department of Obstetrics and Gynaecology, University of Zimbabwe, College of Health Sciences, Harare, Zimbabwe

² Department of Obstetrics and Gynaecology, Parirenyatwa Central Hospital, Harare, Zimbabwe

Corresponding author: E Ziki (enesiaziki@gmail.com)

Uterine inversion is a rare but potentially life-threatening obstetric emergency of unknown aetiology, which is often associated with inadvertent traction on the umbilical cord before separation of the placenta. Here we report a case of a 26-year-old woman who presented with a day's history of uterine inversion after an attempt to remove a retained placenta following a second-trimester miscarriage. Reduction was attempted in casualty without success and she was taken to theatre for surgical reduction under anaesthesia. Reduction was eventually achieved using the Haultain method.

S Afr J Obstet Gynaecol 2017;23(3):78-79. DOI:10.7196/SAJOG.2017.v23i3.1274

Uterine inversion is defined as the 'turning inside out of the fundus into the uterine cavity' and the incidence is about 1 in 3 737.^[1] Active management of the third stage of labour resulted in a 4.4-fold decline in the incidence of uterine inversion.^[1] The main causes of uterine inversion are thought to be mismanagement of the third stage of labour, such as premature traction of the umbilical cord with or without fundal pressure and manual placental removal after delivery before complete placental separation. Other associated factors include nulliparity, a morbidly adherent fundal placenta, short umbilical cord and rare connective tissue disorders. Spontaneous inversion has been reported in about 50% of the cases.^[2,3]

Case report

A 26-year-old patient, who had had two previous normal vaginal deliveries and one miscarriage presented with a day's history of a vaginal mass after an attempted removal of a retained placenta following a miscarriage that was managed at a local hospital. The mass was associated with vaginal bleeding and lower abdominal pain. She also reported having passed a fetus. She was unaware of the current pregnancy because of lactational amenorrhoea and gestation was estimated at a possible 18 weeks based on recent perception of fetal movements. She was using progesterone-only pills for contraception. An attempt to remove the placenta by cord traction at the local hospital resulted in the inversion. She was subsequently referred to Harare Central hospital. On examination she was ill-looking, markedly pale and had a tachycardia of 128 beats per minute. Her blood pressure was 115/55 mmHg and she had a normal urine output of 40 mL/h. Her haemoglobin level was 4.2 g/dL. Her abdomen was soft and non-tender without masses and the uterine fundus was not palpable abdominally. Vaginal examination revealed a globular and firm mass in the vagina; the cervix could not be visualised and the fornices were drawn upwards. A diagnosis

of subacute uterine inversion was made and resuscitation was performed using ringer's lactate fluid and 4 units of packed red blood cells. She was commenced on intravenous antibiotics. A manoeuvre to correct the inversion by placing a cupped hand into the vagina and applying upward pressure, also known as Johnson's manoeuvre, was attempted in casualty to no avail.^[2,3] She was taken to theatre and the procedure was attempted again under anaesthesia without success. We proceeded to do a laparotomy and attempted the Huntington manoeuvre^[2,4,5] during which the round ligaments are identified and upward traction is applied on them, while a cupped hand in the vagina pushes the inverted uterus upwards. Unfortunately, this attempt was unsuccessful. The Haultain^[2,4,5] procedure was then performed where the cervical ring was opened posteriorly at the 6 o'clock position using a 6 cm vertical incision and reversion was achieved. An oxytocin infusion was started and the posterior aspect of the uterus was repaired (Fig. 1).

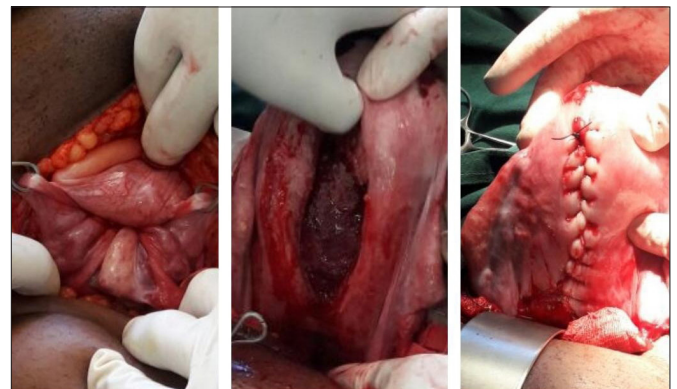


Fig. 1. Uterine inversion seen at laparotomy with a crater in the region of the cervix with in-drawing of the tubes and round ligaments, cervical ring opened posteriorly and closure of the uterus.

Discussion

We present a case of a 26-year-old with subacute uterine inversion which was corrected using Haultain's procedure. Uterine inversion is an emergency which is associated with serious morbidity and mortality if not properly managed. The clinical scenario in this case was unlikely as this patient was in the second trimester of her pregnancy and did not have any previous uterine surgery that may have predisposed her to a morbidly adherent placenta, other than possible curettage following a previous miscarriage. In this case, the attempt to deliver the placenta by cord traction caused the inversion. Uterine inversion can be classified as acute if it occurs within 24 hours, subacute if it occurs within 4 weeks and chronic if it occurs after >4 weeks. Inversion is graded as first, second, third or fourth degree when the fundus is at the cervix, in the vagina, at the introitus, or exteriorised, respectively. The diagnosis for our case was a second-degree subacute inversion. Diagnosis is usually clinical and most patients (94%) present with significant haemorrhage, with or without shock.^[3] Shock may sometimes be neurogenic in origin owing to the excruciating pain. The differential diagnoses include a prolapsed fibroid and pelvic organ prolapse. Management involves resuscitation and promptly attempting reduction.

Non-surgical management

The Johnson manoeuvre,^[3] which was initially attempted in this case has a success rate of 43 - 88% – this rate improves the earlier the manoeuvre is attempted.^[2,3] Tocolytics may be administered to make the procedure easier but it was not given because of the risk of worsening the shock. Uterotonics are administered after successful reduction to prevent re-inversion and antibiotics are used to prevent endometritis.

The hydrostatic method recommended by the World Health Organization, which was described by O'Sullivan in 1945, was not attempted in this case as 24 hours had already elapsed since the inversion – the method was therefore unlikely to be successful and would increase the risk of infection.^[2,5] The hydrostatic method is performed in an operating theatre with the woman in the lithotomy position; sterile water or normal saline is rapidly instilled into the vagina using a fluid-giving set with a tight seal at the introitus using hands or preferably a silastic ventouse cup. The fundus is pushed into the natural position as fluid fills and distends the vagina. The complications of this method may be infection, procedure failure and saline embolism.

Surgical methods

Non-surgical methods usually suffice and therefore the need for surgery is rare. The Spinelli and Kustner^[5] operations consist of

an anterior and posterior median colpohysterotomy through the vaginal access for removal of the cervical ring. The abdominal route is preferred over the vaginal route as it allows more efficient control of the haemorrhage and a smaller incision on the uterus, which can easily be sutured. The Huntington method, which was initially attempted at laparotomy, is less invasive than the Haultain method as it is purely mechanical and does not involve incisions on the uterus and its appendages. Our attempt was unsuccessful owing to the oedematous constriction ring formed by the cervix.

We used the Haultain abdominal hysterotomy method with a good surgical outcome. Laparoscopic reduction has been used successfully in a case by Vijayaraghavan *et al.*^[6] but our patient was not haemodynamically stable and therefore we could not consider the method in our case. Our patient was counselled before discharge on the need to have a caesarean section in the next pregnancy because the posterior vertical incision which extends to the uterine body carries a high risk of uterine rupture.

Conclusion

Uterine inversion is a rare and life-threatening emergency, which calls for swift action from the managing clinicians. Clinicians in obstetric care should include management of uterine inversion in their obstetric emergency drills.

Acknowledgements. Prof. T Zvandasara for his guidance in the management of this and other cases.

Authors contributions. E Ziki – managed case, compiled manuscript, critical revision and editing. S Madombi – managed case, compiled manuscript, critical revision and editing. C Chidhakwa – managed case, critical revision and editing. M Madziyire – compiled manuscript, critical revision and editing. N Zakazaka – managed case, critical revision and editing.

Funding. None.

Conflict of interests. None.

1. Baskett TF. Acute Uterine Inversion: A Review of 40 Cases. *J Obstet Gynaecol Can* 2002;24(12):953-956. [https://doi.org/10.1016/S1701-2163\(16\)30594-1](https://doi.org/10.1016/S1701-2163(16)30594-1)
2. Bhalla R, Wuntakal R, Odejinmi F, Khan RU. Acute inversion of the uterus. *Obstetrician Gynaecologist* 2009;1(1):13-18. <https://doi.org/10.1576/toag.11.1.13.27463>
3. Ojabo AO, Adesiyun AG, Ifenne DI, Hembur-Hilekan S, Umar H. Acute uterine Inversion: A case report and literature review. *AIMS* 2015;5(1):52-55. <https://doi.org/10.4103/2278-9596.153166>
4. Rocconi RH, Huh WK, Chiang S. Postmenopausal uterine inversion associated with endometrial polyps. *Obstet Gynaecol* 2003;102(3):521-523.
5. Ward HRG. O'Sullivan's hydrostatic reduction of an inverted uterus: sonar sequence recorded. *Ultrasound Obstet Gynecol* 1998;12(4):283-286. <https://doi.org/10.1046/j.1469-0705.1998.12040283>
6. Vijayaraghavan R, Sujatha Y. Acute postpartum uterine inversion with haemorrhagic shock: laparoscopic reduction: a new method of management? *BJOG* 2006;113(9):1100-1102. <https://doi.org/10.1111/j.1471-0528.2006.01052.x>

Accepted 8 December 2017.