

Non-palpable and difficult contraceptive implant removals: The New Somerset Hospital referral-clinic experience

G A Petro, MB ChB (UCT), FCOG (SA)

Department of Obstetrics and Gynaecology, New Somerset Hospital, Cape Town; and University of Cape Town, South Africa

Corresponding author: G A Petro (Gregory.Petro@westerncape.gov.za)

Subdermal contraceptive implants are one method of long-acting reversible contraception. Implanon NXT provides contraception for 3 years, and Jadelle for 5 years. Women are advised to have the implant removed or replaced once the expiry date has been reached. The implants are easy to remove through a small opening in the skin. In a small proportion of women the implant will not be palpable or, very rarely, may have migrated. Non-palpable and migrated implants can be removed in an outpatient setting, by doctors who are specially trained and have access to ultrasound and special instruments. This article describes the specialist referral clinic for deep and difficult contraceptive implant removals at a regional hospital in Cape Town, South Africa.

S Afr J Obstet Gynaecol 2017;23(3):101-104. DOI:10.7196/SAJOG.2017.v23i3.1229

Subdermal hormonal contraceptive implants provide women with long-acting reversible contraception. These methods have low failure rates and high continuation rates, making them very effective forms of reversible contraception.^[1] The single-rod etonogestrel-containing implant (Implanon NXT, MSD (Pty) Ltd, South Africa(SA)) was released in SA in 2014. Implanon NXT is also marketed internationally as Nexplanon. Compared to the original Implanon, the newer rod contains barium sulphate, making it visible on X-Ray.^[2] In the Western Cape Province of SA, ~70 000 Implanon NXT rods were inserted between 2014 and 2016. Nationally, 800 000 implants were inserted in the first 2 years up to March 2016.^[3] This number is likely to increase, as healthcare workers and clients appreciate the benefits of long-term reversible contraceptive methods, while governments and support agencies reduce barriers to the use of these methods.^[4]

Because Implanon NXT expires after 3 years, patients have been presenting to clinics in large numbers for removals or replacements since February 2017. The majority of these implants are easy to remove. The removal can be performed by a nurse or doctor who has had basic training in the procedure.^[5] The basic removal technique is termed the pop-out technique.^[6] Some of these implants are difficult to remove and require referral to a special clinic.^[7] In SA, patients who request implant removals do not present themselves primarily to specialist gynaecologists; general practitioners and primary healthcare nurses and doctors will all be faced with the challenge of removing or replacing contraceptive implants.

In the Western Cape Province public health facilities, only Implanon NXT is available. However, there are a number of patients with the double rod Jadelle implant who are presenting to local clinics for removal. Jadelle is a 5-year levonorgestrel-containing implant that is available in other provinces in SA, as well as in other southern African countries. Jadelle tends to form a fibrous capsule around the implants and this, together with the fact that the rods are softer than Implanon NXT, makes them more difficult to remove safely without a long skin incision, sometimes requiring sutures.^[6,8]

Service delivery before establishment of the referral clinic

Prior to February 2017, the patients requesting removals were doing so before the expiry date. Worldwide, the retention rate of contraceptive implants after 1 year varies between 75 and 88%.^[10,13-15] The main reasons for requesting early removals were side-effects,^[9-11] changing to another method, planning to conceive and concerns about the interaction between the Implanon and antiretroviral medication.^[12]

In a small proportion of patients requesting removal, the implant was not palpable. There were also patients referred with failed attempted removals. Before February 2017, the practice in Western Cape public-sector hospitals was to attempt these difficult removals under general anaesthesia in an operating theatre, using x-ray localisation. This method of removal was not only time-consuming, but also used scarce operating theatre resources and a radiographer, and often orthopaedic or vascular surgeons were called to assist owing to the poor localisation of the implant and the potential risk of nerve or vascular damage.^[16]

These patients often endured long procedures under general anaesthesia, and inevitably had long scars that required skilful suturing to avoid disfigurement. Frequently, there were multiple disruptions to the removal procedure, owing to the repositioning of various instruments and clips to gain closer proximity to the likely location of the implant. Other authors have reported similar experiences.^[17,18]

Service delivery after the establishment of the referral clinic

On 9 February 2017, the NDoH, supported by the company MSD, provided training for the removal of non-palpable contraceptive implants in the Western Cape Province. Three specialists were trained in the removal of deep and non-palpable contraceptive implants using simultaneous ultrasound localisation and customised removal instruments under local anaesthetic in an outpatient clinic setting. On 14 February, a specialist referral clinic for deep and

non-palpable contraceptive implants was established at New Somerset Hospital, Green Point, in the Metro West area of the City of Cape Town Health District.

Referral requirement, criteria and referral pathways

It is important to assess the need for the number of deep and difficult implant removals and to provide a safe and accessible service to patients and referring clinicians, nurses and doctors.^[11] Within that referral pathway it is important to provide training and clinical governance for all implant removals, including those simple and routine.

The referral criteria to the clinic at New Somerset Hospital:

- Deep or non-palpable implants
- Failed attempted removals
- Implants that have migrated from the original insertion site
- Jadelle implants.

Ultrasound techniques and specifications

The implants are located in three dimensions, but conventional 2-dimensional ultrasound equipment is used in musculoskeletal ultrasonography to visualise superficial structures.^[7] Ultrasound is used at the time of the procedure, although preoperative ultrasound and skin marking in a radiology suite has been described.^[7]

The implant is first located in the sagittal plane by scanning the arm longitudinally.^[19] The implant is visible in the transverse plane by its characteristic posterior acoustic shadow.^[20] Simultaneously, the depth of the implant can be determined. While the actual depth is not important, what is important is to establish whether the implant is above or below the fascia covering of the muscle. Most (~70%) of the deep implants are in the subcutaneous fat layer and not in the muscle.^[21] When the implant is in the muscle, ultrasound is useful to check for blood vessels and nerves in close proximity to the implant. Finally, the M-mode of the ultrasound is employed to locate the implant in the coronal plane by scanning the arm circumferentially.

The ultrasound specifications for this technique:

- High frequency linear array probe
- Frequency 10 MHz - 18 MHz
- High-resolution monitor

- Colour Doppler
- B-mode (standard)
- M-mode (cardiac).

Removal techniques

Ultrasound localisation allows for 1 - 2 mL of local anaesthetic agent to be injected subdermally at the precise location of the implant. The procedure is then dependent on the depth of the implant. For implants in the subcutaneous fat layer, a small <3 mm skin incision is made with a no. 11 blade over the midpoint of the implant. The tissue is separated using a mosquito forceps or a straight artery forceps. A modified vasectomy clamp is inserted through the small incision. The ringed portion of the instrument has a 2.2 mm diameter that fits around the 2 mm implant.^[7] The implant is grasped and brought to the skin surface. Excess tissue is removed by blunt or sharp dissection as needed, and the implant is removed (Fig. 1). The skin is approximated with a steristrip if needed, and covered with a suitable dressing.

When the implant is located beneath the fascial layer covering the muscle (Fig. 2), a wider incision is required. The localisation, skin markings and local anaesthetic are the same as for the implant in the fat layer. It is important to use a local anaesthetic with adrenaline (e.g. Xylotox E80A). A 1.5 - 2 cm incision is made in the skin using a no. 11 blade. The subcutaneous tissue is separated using a mosquito forceps or straight artery forceps. Once the muscle fascia is exposed, the forceps is used to feel for the implant in the muscle. Two small right-

angled retractors are inserted on either side of the implant. The fascia is opened longitudinally and the implant is grasped with the modified vasectomy forceps or another forceps. If the implant is buried in the muscle, careful dissection is performed to locate and release the implant. Once the implant is removed, the skin is closed with two interrupted mattress sutures. Vicryl, nylon or silk can be used, preferably no. 2/0, on a cutting needle.

Instruments for deep implant removals

Special instruments are required for successful removal of non-palpable or deeply inserted contraceptive implants. Using these instruments and the techniques described above it is possible to safely and effectively remove deeply inserted implants with local anaesthesia in an outpatient clinic setting.

The instruments for deep implant removals:

- 1 scalpel handle for no. 11 blade
- 1 mosquito forceps
- 1 modified vasectomy clamp (2.2 mm diameter ring portion)
- 2 straight artery forceps
- 2 small (0.5 cm wide) right angle retractors
- 1 needle holder
- 1 stitch scissors
- 1 toothed tissue forceps.

Consumables for deep implant removals

The consumables or equivalent replacements are generally available in all clinics where minor surgical procedures are performed.

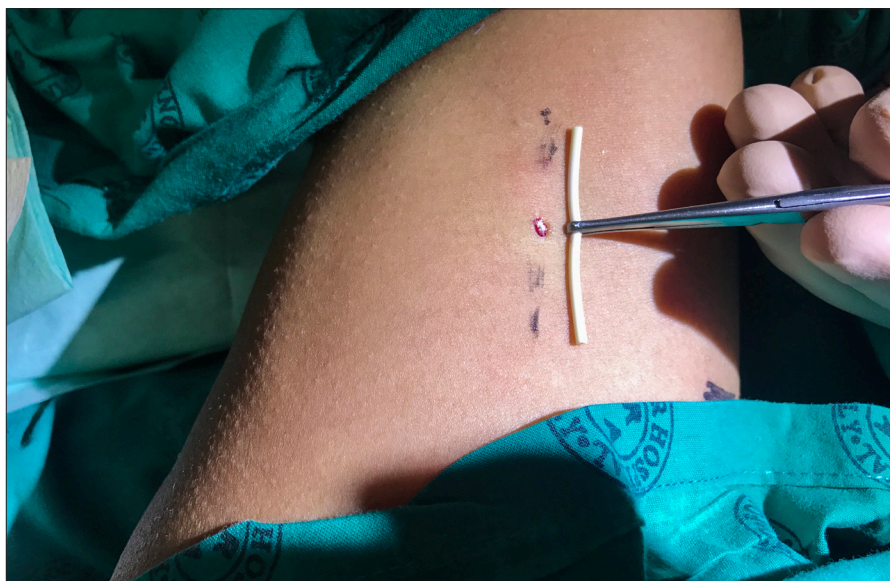

Fig. 1. Implant in modified vasectomy clamp, showing the small incision.

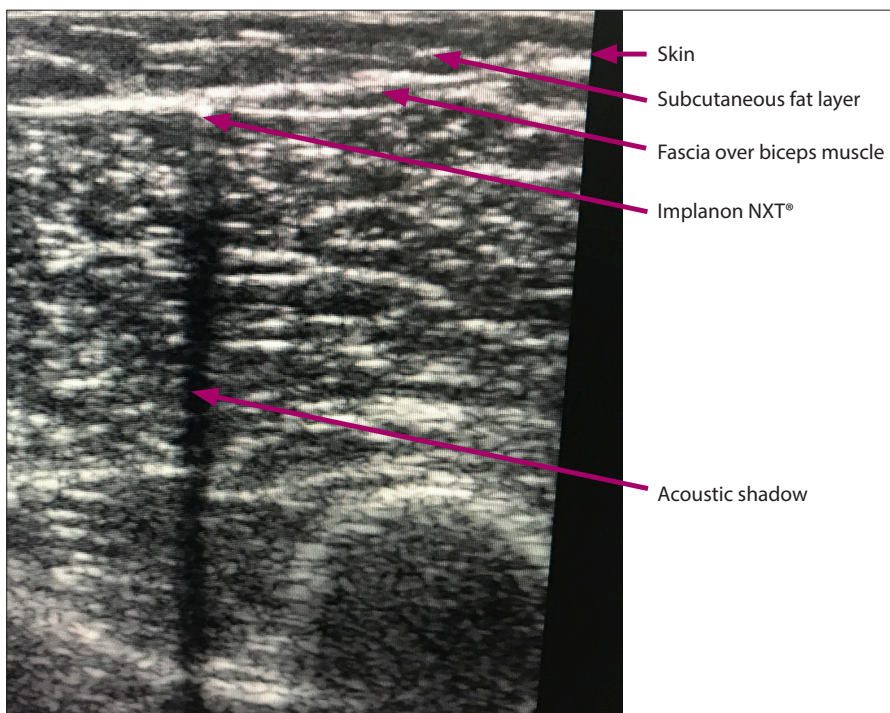


Fig. 2. Ultrasound image. The implant is the white dot beneath fascia. Long acoustic shadow is demonstrated.

The list of the consumables that are used in the New Somerset Hospital clinic is provided here as a guide:

- 1 amp (1.8 mL dental cartridge) containing lidocaine 1% with adrenaline (e.g. Xylotox E80A)
- 22 G, 32 mm injection needle (black hub)
- 2 mL or 5 mL syringe
- sterile gloves
- povidone (Betadine) or chlorhexidine (Hibitane) solution to clean the skin
- Cidex or similar sterilising solution
- alcohol swabs (Webcol or similar)
- no. 11 scalpel blade
- no. 2/0 vicryl suture on a cutting needle (silk or nylon can also be used)
- gauze swabs
- steristrip, swab and dressing plaster
- ultrasound gel
- permanent marker pen.

Discussion

Hormonal contraceptive implants were launched in SA in February 2014. Implanon NXT is a single rod system containing etonogestrel 68 mg, and it is the only contraceptive implant available in the Western Cape public health sector. The single rod implant lasts for 3 years, and patients are now returning for its removal, with or without its replacement.

The majority of these implants can be removed by trained nurses and doctors at primary healthcare facilities. No special

instruments are needed for routine removals. Non-palpable and deeply inserted contraceptive implants are difficult to locate. The most common reason for non-palpable and migrated implants is incorrect insertion technique, most notably not tenting the skin to ensure subdermal placement.^[1] Accurate localisation is crucial for safe and effective removal through the smallest, least traumatic skin incision possible. Exploratory surgery without knowledge of the exact location of the implant is not an acceptable standard of practice.^[7]

The acceptability and continued use of any contraceptive method is dependent on patient experience and community attitudes, and not only the clinical effectiveness of the method.^[4] For contraceptive implants, the removal will become as critical to public opinion as are the insertion and perceived side-effects of the method. As healthcare providers, we must ensure the safe and efficient removal of contraceptive implants, and provide a repeat insertion at the same time as removal if requested by the patient.

Conclusion

Fig. 3 summarises the key practice points in implant removal. Contraceptive implants, if inserted correctly and if the patient has not gained excessive weight, should be easy to remove.^[22] Non-palpable and difficult removals of contraceptive implants should be performed by specially trained practitioners

- Practitioners who are trained to insert implants should also be trained to remove them.
- Exploratory surgery without knowledge of the exact location of the implant is strongly discouraged.
- Simultaneous ultrasound location and removal with specially designed instruments is the preferred method of removal of deeply inserted implants.
- This procedure is best performed using a local anaesthetic in an outpatient clinic setting.
- Referral to a specialist with experience in difficult implant removals is recommended.

Fig. 3. Practice points.

using custom-designed instruments. These implants should be removed under local anaesthetic using ultrasound localisation in an outpatient clinic setting.^[6,7]

Acknowledgements. I would like to acknowledge Dr Malika Patel who assisted me with the first cases. Thank you to Prof. Landon Myer and Ms Lyndsey Petro for help with preparing and editing the manuscript.

Author contributions. Sole author.

Funding. None.

Conflicts of interest. None.

1. Espey E, Ogburn T. Long-acting reversible contraceptives: Intrauterine devices and the contraceptive implant. *Obstet Gynecol* 2011;117(3):705-719. <https://doi.org/10.1097%2F00013e31820ce2f0>
2. Mansour D. Nexplanon: what Implanon did next. *J Fam Plan Reprod Health Care* 2010;36(4):187-189. <https://doi.org/10.1783%2F147118910793048629>
3. Mullick, MF Chersich, Y Pillay, H Rees. Introduction of the contraceptive implant in South Africa: Successes, challenges and the way forward. *S Afr Med J* 2017;107(10):812-814. <https://doi.org/10.7196/SAMJ.2017.v107i10.12849>
4. Duvall S, Thurston S, Weinberger M, Nuccio O, Fuchs-Montgomery N. Scaling up delivery of contraceptive implants in sub-Saharan Africa: Operational experiences of Marie Stopes International. *Glob Health Sci Pract* 2014;2(1):72-92. <https://doi.org/10.9745%2Fghsp-d-13-00116>
5. Mascarenhas L. Insertion and removal of Implanon. *Contraception* 1998;58(Suppl 6):S79-S83. <https://doi.org/10.1016%2Fs0010-7824%2898%2900121-8>
6. Mansour D, Walling M, Glenn D, et al. Removal of non-palpable etonogestrel implants. *J Fam Plan Reprod Health Care* 2008;34(2):89-91. <https://doi.org/10.1783%2F147118908783972078>
7. Chen MJ, Creinin MD. Removal of a nonpalpable etonogestrel implant with preprocedure ultrasonography and modified vasectomy clamp. *Obstet Gynecol* 2015;126(5):935-938. <https://doi.org/10.1097%2F0000000000001082>
8. Levine JP, Sinosky FE, Christ MF, Implanon US Study Group. Assessment of Implanon insertion and removal. *Contraception* 2008;78(5):409-417. <https://doi.org/10.1016%2Fj.contraception.2008.06.016>
9. Flore M, Chen XL, Bonney A, et al. Patients' perspectives about why they have their contraceptive Implanon NXT device removed early. *Austr Fam Physician* 2016;45(10):740-744.
10. Croxatto HB, Urbancsek J, Massai R, Bennink HC, van Beek A. A multicentre efficacy and safety study of the single contraceptive implant Implanon. *Hum Reprod* 1999;14(4):976-981. <https://doi.org/10.1093%2Fhumrep%2F14.4.976>
11. Darney P, Patel A, Rosen K, Shapiro LS, Kaunitz AM. Safety

RESEARCH

- and efficacy of a single-rod etonogestrel implant (Implanon): Results from 11 international clinical trials. *Fertil Steril* 2009;91(5):1646-1653. <https://doi.org/10.1016%2Fj.fertnstert.2008.02.140>
12. Vieira CS, Bahamondes MV, de Souza RM, et al. Effect of antiretroviral therapy including lopinavir/ritonavir or efavirenz on etonogestrel-releasing implant pharmacokinetics in HIV-positive women. *J Acquir Imm Defic Syndr* 2014;66(4):378-385. <https://doi.org/10.1097%2Fqai.0000000000000189>
13. Glasier A. Implantable contraceptives for women: effectiveness, discontinuation rates, return of fertility, and outcome of pregnancies. *Contraception* 2002;65(1):29-37. <https://doi.org/10.1016%2Fs0010-7824%2801%2900284-0>
14. Lakha F, Glasier AF. Continuation rates of Implanon in the UK: data from an observational study in a clinical setting. *Contraception* 2006;74(4):287-289. <https://doi.org/10.1016%2Fj.contraception.2006.05.072>
15. Obijuru L, Bumpus S, Auinger P, Baldwin CD. Etonogestrel implants in adolescents: Experience, satisfaction, and continuation. *J Adolesc Health* 2016;58(3):284-289. <https://doi.org/10.1016%2Fj.jadohealth.2015.10.254>
16. Navani M, Robinson C. Clinical challenge with Implanon removal: A case report. *J Fam Plan Reprod Health Care* 2005;31(2):161-162. <https://doi.org/10.1783%2F1471189053629437>
17. Vidin E, Garbin O, Rodriguez B, Favre R, Bettahar-Lebugle K. Removal of etonogestrel contraceptive implants in the operating theater: Report on 28 cases. *Contraception* 2007;76(1):35-39. <https://doi.org/10.1016%2Fj.contraception.2007.03.012>
18. Nouri K, Pinker-Domenig K, Ott J, Fraser I, Egarter C. Removal of non-palpable Implanon with the aid of a hook-wire marker. *Contraception* 2013;88(4):577-580. <https://doi.org/10.1016%2Fj.contraception.2013.05.002>
19. Gabriel H, Shulman L, Marko J, Nikolaidis P, Chirita V. Compound versus fundamental imaging in the detection of subdermal contraceptive implants. *J Ultrasound Med* 2007;26(3):355-359. <https://doi.org/10.7863%2Fjum.2007.26.3.355>
20. Lantz A, Noshier JL, Pasquale S, Siegel RL. Ultrasound characteristics of subdermally implanted Implanon contraceptive rods. *Contraception* 1997;56(5):323-327. <https://doi.org/10.1016%2Fs0010-7824%2897%2900159-5>
21. Mansour D, Fraser IS, Walling M, Glenn D, Graesslin O. Methods of accurate localisation of non-palpable subdermal contraceptive implants. *J Fam Plan Reprod Health Care* 2008;34(1):9-12. <https://doi.org/10.1783%2F14711890878332285>
22. Pearson S, Stewart M, Bateson D. Implanon NXT: Expert tips for best-practice insertion and removal. *Aust Fam Physician* 2017;46(3):104-108.

Accepted 3 December 2017.