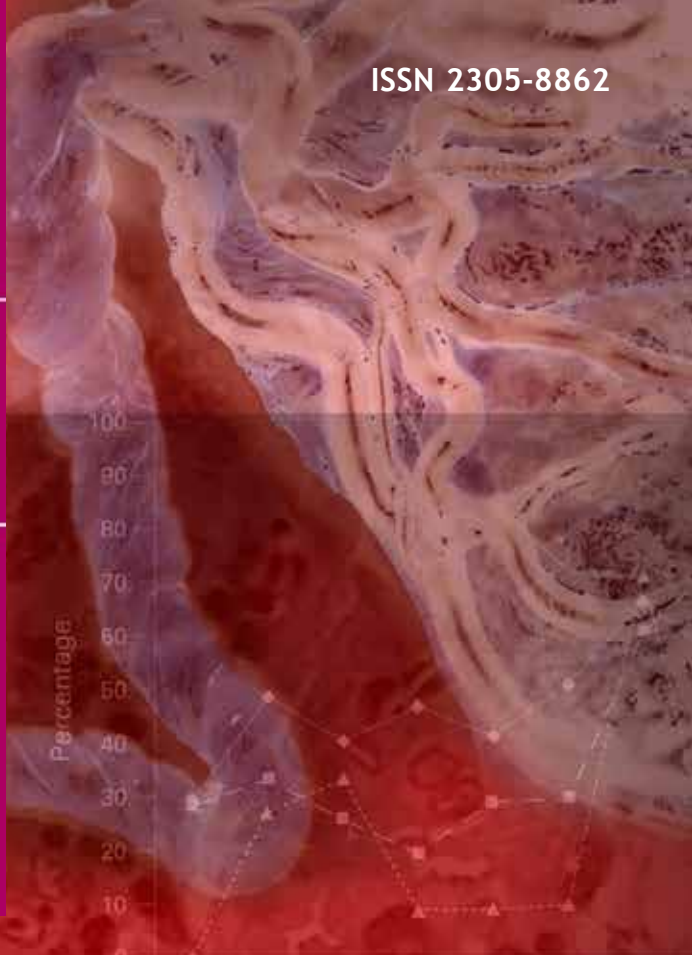


SAJOG

May 2017
Vol. 23 No. 1

THE SOUTH AFRICAN JOURNAL OF
OBSTETRICS AND GYNAECOLOGY

- Abnormal umbilical artery Doppler velocimetry and placental histopathological correlation in fetal growth restriction
- Preventive role of low-molecular-weight heparin in unexplained recurrent pregnancy loss
- A cross-sectional descriptive study of breastfeeding behaviour and galactagogue use among private-sector patients in Cape Town, South Africa
- Bilateral synchronous benign ovarian neoplasm: A rare occurrence



	Jan	Feb	Mar	Apr	May	June	July
Pre-eclampsia patients managed according to standards (%)	29	49	40	47	41	51	67
Haemorrhage patients managed according to standards (%)	28	33	26	20	29	30	61
Sepsis patients managed according to standards (%)	0	27	53	9	9	10	21

